

Bovine Lung Insufflation as a Dynamic Model for Teaching Respiratory Anatomy and Physiology: A Comparative Educational Approach

Orozco–Pira¹, Wendy Johanna², Villa - Ramírez Rigoberto³

^{1,2}Zootechnics Program, Tenth Semester, University of Quindío Armenia, Colombia

³Zootechnics Director Program

Abstract: *The insufflation technique as a method to preserve and study the morphology of bovine lung models. This study aimed to evaluate the insufflation technique as a preservation method in the morphological study of bovine lung models, describing their anatomical and functional characteristics. Fresh bovine lungs were used and subjected to controlled insufflation to observe structural changes in the lobes, bronchi, and alveoli. The results demonstrated considerable distensibility of the bovine lungs, allowing homogeneous expansion of the lobes and clear differentiation of anatomical structures, such as interlobar fissures and main airways. The lobes showed significant expansion without evidence of collapse or tissue damage, enabling detailed observation of the internal lung architecture. These findings underscore the utility of bovine lung models in morphological studies, providing valuable information on the structure and behavior of lung tissues under controlled insufflation. The insufflation technique as a method to preserve and study the morphology of bovine lung models.*

Keywords: pulmonary insufflation, bovine lungs, anatomy teaching, respiratory training, veterinary education

1. Introduction

The respiratory system is vital in vertebrate physiology due to its role in gas exchange, essential for homeostasis and survival. The structural and functional complexity of human lungs presents significant challenges for education in respiratory anatomy and physiology. Traditionally, teaching methods have included simulations, human and animal cadavers, and computational models (Hixon et al., 2019). However, animal models, particularly bovine lungs, offer a valuable alternative due to their anatomical and functional similarity to human lungs, along with their relative affordability and availability (Fung, 1993).

Bovine lungs present anatomical characteristics that make them suitable for comparative studies. These include the structural organization of lobes, bronchi, and alveoli, which, although not identical to human lungs, provide a useful approximation for understanding respiratory physiology (Bryant et al., 2006). Controlled insufflation of bovine lungs enables clear visualization of internal structures, facilitating the analysis of morphology and functionality under controlled experimental conditions (Hodgson et al., 2014). Previous studies have shown that bovine lung insufflation can provide detailed insights into lobe structure, airway differentiation, and alveolar organization without evidence of collapse or tissue damage during the preservation process (Levy et al., 2010). These observations suggest that bovine lungs are an invaluable resource for teaching respiratory anatomy and physiology, allowing direct and detailed evaluation of pulmonary morphology (Ramsay et al., 2012).

This study aimed to examine the pulmonary morphology of bovine models through the insufflation technique, highlighting their macroscopic anatomical and functional characteristics. Fresh bovine lungs were subjected to controlled insufflation to observe structural changes in the lobes and bronchial system. The study seeks to provide

insights into the utility of the bovine lung model in morphological research, significant challenges in teaching respiratory anatomy and physiology.

2. Materials and Methods

Specimens:

Bovine lungs were obtained from slaughterhouses registered with the Ministry of Social Protection and donated by the University of Quindío. The specimens were selected based on size and structural similarity to human lungs, specifically from bovines approximately seven months postnatal, as per the criteria described by Pratt and Klugh (1961).

Exclusion criteria:

Specimens were excluded if they showed visible anatomopathological alterations, as assessed by veterinary health inspectors.

Insufflation process:

A compressed air source was connected to the trachea, applying controlled pressures between 20 and 30 cmH₂O to simulate pulmonary ventilation.

Materials:

- Fresh bovine lungs
- Manual insufflation system (manual air pump with flexible tubing)
- Manometer (pressure not exceeding 25 cmH₂O)
- Dissection instruments (scalpels, surgical scissors, forceps, retractors)
- Camera (Fuji X - T200, macro capability)
- 10% formaldehyde solution and powdered naphthalene

Procedures

- 1) **Specimen preparation:** The lungs were washed with 10% formaldehyde and filled with powdered naphthalene

through the trachea to aid preservation. An initial insufflation of 10 cmH₂O was applied, followed by continuous cycles over a 24 - hour period

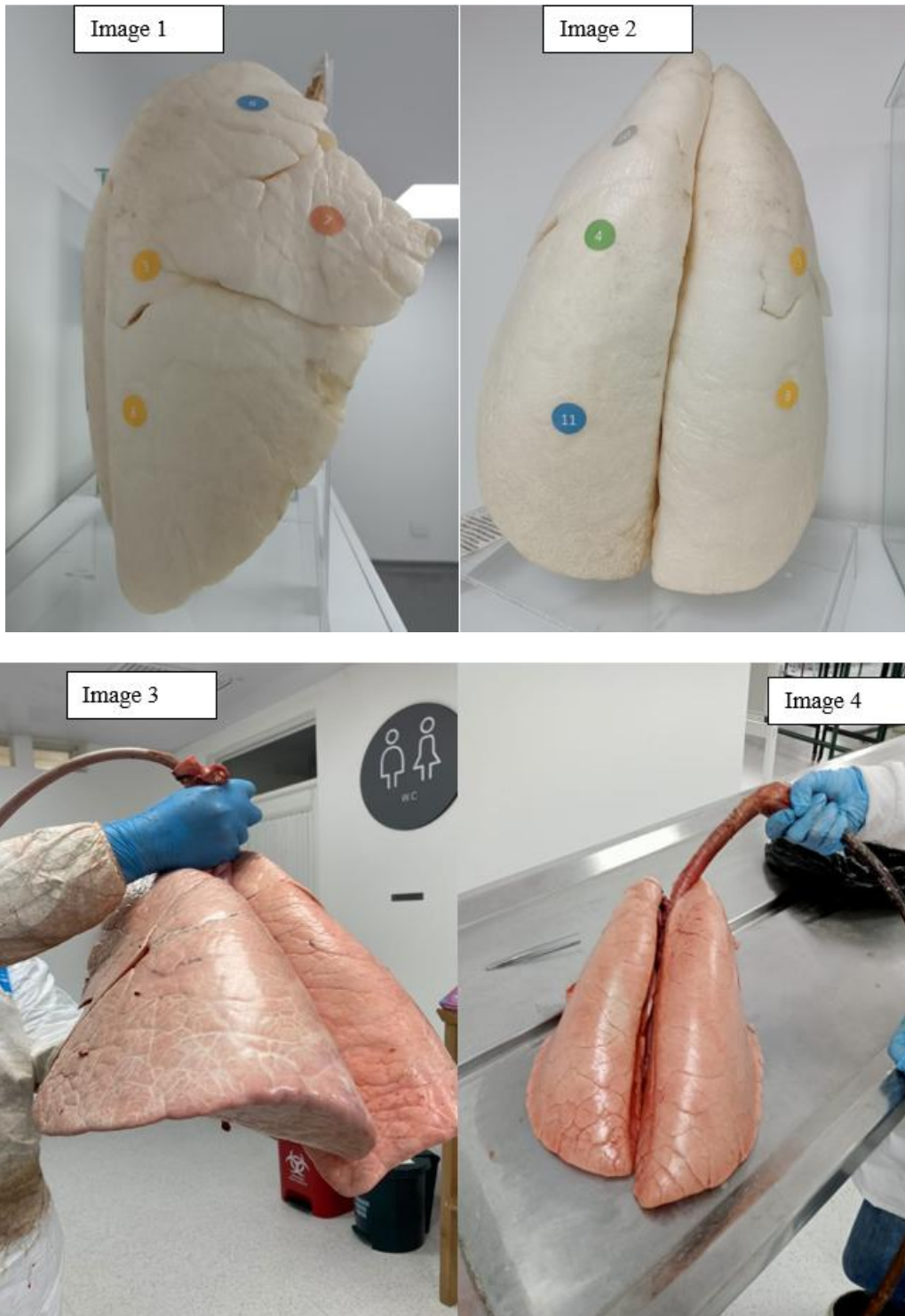
- 2) **Pulmonary insufflation:** Air pressure was gradually increased to 25 cmH₂O to achieve homogeneous lobe expansion, with repeated cycles of insufflation and deflation to observe dynamic pulmonary behavior.
- 3) **Macroscopic observation:** Direct observation focused on the lobes, bronchi, and interlobar fissures, with special attention to structural integrity during insufflation and deflation.
- 4) **Visual documentation:** Photographs documented the insufflation phases and anatomical structures for subsequent analysis.

- 5) **Data analysis:** Qualitative descriptions of pulmonary morphology, including lobe arrangement and expansion behavior, were recorded across insufflation cycles. The study focused on macroscopic morphology without histological analysis.

3. Results and Discussion

Pulmonary Volume and Elasticity:

Bovine lungs demonstrated high elasticity, retaining between 6 and 8 liters of air. Full lobe expansion allowed clear visualization of anatomical landmarks such as lobar divisions and airways.



The tissue showed appropriate distensibility, maintaining uniform expansion without rupture under controlled pressures.

Images 1 and 2 show the lung insufflation process. The images below, **Images 3 and 4** display the anterior view of the tracheopulmonary block, preserved through insufflation. **Image 3:** (10) Upper lobe; (4) Middle lobe; (11) Lower lobe; (8) Lower lobe; (3) Upper lobe. **Image 4:** (7) Inferior lingular segment; (3) Superior lingular segment.

Tissue Behavior:

Lung tissues returned effectively to their resting state after each insufflation cycle, without signs of bronchial collapse. This indicated good preservation of biomechanical properties, allowing repeated observation of pulmonary insufflation dynamics.

Educational Relevance:

Direct manipulation of bovine lungs provides tactile and visual learning experiences that reinforce theoretical knowledge. Unlike virtual models, real tissues allow students to experience pulmonary elasticity, observe insufflation capacity, and examine morphological responses, bridging the gap between theory and clinical practice (Smith & Jones, 2012).

Bovine lungs also serve as ethical and cost - effective alternatives to live animal models, offering a realistic simulation environment for procedures such as tracheal intubation and mechanical ventilation (Roberts et al., 2019). Their use maximizes resource utilization and aligns with ethical standards in veterinary education (Duncan et al., 2016).

Comparative Advantages:

Compared to high - tech simulators, bovine lungs provide accessible and effective training opportunities, especially for institutions with limited resources (Levin et al., 2019). Their anatomical similarity to other mammalian species makes them versatile tools for both veterinary and medical training.

4. Conclusions

The insufflation of bovine lungs has proven to be a valuable tool for both research and teaching, offering clear insights into pulmonary architecture and dynamic behavior. This model facilitates comprehensive learning in respiratory physiology and comparative anatomy, strengthening the clinical training of students and professionals. Future research should assess the effectiveness of this model against advanced simulators, as well as its longterm impact on knowledge retention and clinical skill development.

References

- [1] Allen, J., McLaughlin, R., & Wong, M. (2015). Comparative anatomy and physiology of the respiratory system in large animals. *Journal of Veterinary Medicine*, 12 (3), 232–245.
- [2] Brown, G., Hume, D., & Morton, C. (2018). Challenges in transitioning from theoretical learning to clinical practice in veterinary education. *Veterinary Education Today*, 16 (2), 98–105.
- [3] Bryant, A. E., et al. (2006). Comparative anatomy of the bovine and human lung. *Journal of Anatomy*, 208 (3), 361–368.
- [4] Davies, A., & Linch, P. (2010). Animal models in the study of respiratory physiology. *Journal of Experimental Biology*, 213 (3), 512–519.
- [5] Duncan, A., Turner, S., & Price, C. (2016). Ethical considerations in the use of animal models in veterinary education. *Veterinary Journal of Ethics*, 12 (4), 120–132.
- [6] Dunning, D., Freedman, E., & Clark, P. (2018). Evaluating the impact of hands - on models in veterinary anatomy education. *Journal of Veterinary Education*, 45 (1), 89–95.
- [7] Fung, Y. C. (1993). *Biomechanics: Mechanical properties of living tissues* (2nd ed.). Springer.
- [8] García, R. (2018). Didactic strategies for teaching pulmonary physiology. *Medical Education*, 20 (2), 145–151.
- [9] Hixon, J. G., et al. (2019). Advances in respiratory physiology teaching methods. *Respiratory Medicine*, 153, 80–88.
- [10] Hodgson, J. A., et al. (2014). Lung morphometry: Normal and abnormal lungs. *Journal of Applied Physiology*, 116 (1), 88–99.
- [11] LeBlanc, J., Clark, K., & Hansen, M. (2013). The role of simulation in veterinary education. *Veterinary Medical Education Review*, 9 (1), 33–45.
- [12] Levin, G., Robson, C., & Kent, M. (2019). Cost - effective teaching models in veterinary education: A systematic review. *Veterinary Practice*, 24 (6), 322–330.
- [13] Levy, M. N., et al. (2010). Pulmonary function and the use of bovine lungs in research. *American Journal of Physiology*, 298 (4), L572–L582.
- [14] Mendoza, L. (2015). The use of animal models in teaching human anatomy. *Journal of Medical Science Education*, 12 (1), 23–31.
- [15] Pratt, P. C., & Klugh, G. A. (1961). A technique for the study of ventilatory capacity, compliance, and residual volume of excised lungs and for fixing, drying, and serial sectioning in the inflated state. *American Review of Respiratory Disease*, 83 (6), 690.
- [16] Ramsay, J. S., et al. (2012). Evaluating anatomical models for respiratory system education. *Medical Education*, 46 (2), 134–143.
- [17] Roberts, A., Johnson, R., & Williams, E. (2019). Improving veterinary students' skills in respiratory physiology using animal models. *Journal of Veterinary Education*, 47 (4), 211–218.
- [18] Roberts, A., Kent, M., & McKenzie, J. (2016). Enhancing veterinary education with handson models: The role of bovine lungs. *Veterinary Education Research*, 14 (2), 73–81.
- [19] Smith, T., & Jones, M. (2012). Comparative anatomy of the respiratory system in mammals. *Veterinary Science Research*, 8 (4), 102–109.
- [20] Smith, T., Alvarez, S., & Brown, G. (2017). Ethical frameworks for the use of animal models in veterinary education. *Veterinary Journal of Ethics*, 16 (2), 178–192.

- [21] Stewart, R., & Carter, A. (2019). Advancing veterinary education through the use of animal models. *Journal of Veterinary Medicine*, 28 (4), 200–215.
- [22] Thompson, J., & Williams, D. (2015). The use of bovine lungs in veterinary physiology classes. *Veterinary Practice Today*, 11 (3), 145–153.
- [23] Turner, D., & Webb, P. (2017). Veterinary students' perceptions of hands - on models in anatomy and physiology classes. *Veterinary Education Research Journal*, 12 (4), 167–181.
- [24] Weber, K., & Johnson, A. (2019). The future of animal models in veterinary education: Challenges and opportunities. *Veterinary Practice Review*, 27 (3), 89–105.