

A Case Report of Systemic Steroid Therapy for False Brain Tumors in Children

Dipjyoti Baishya, Utpal Kumar Misra

Abstract: ***Study design:** Case report. **Purpose:** to study the efficacy of systemic steroid in pediatric pseudotumor cerebri. **Introduction:** Pseudotumor cerebri is a condition caused by elevated intracranial pressure presenting most commonly with headache. It is a diagnosis of exclusion. **Methods:** A 15 year old girl presented in our OPD with headache since 3months, more in the posterior aspect, continuous type with severe intensity, non - radiating. On examination, her best corrected visual acuity in right eye was 6/9 and left eye was 6/6parts. She had normal anterior segment, normal IOP. Fundoscopy showed both optic discs edematous, pink in color with blurry disc margins, tortuous disc vessels, edematous peripapillary area. Rest of the retina was normal. Lumbar puncture showed elevated opening CSF pressure and normal CSF composition. Hence, she was diagnosed with IIH. She was started on oral prednisolone 1mg/kgbw once a day dosage, oral acetazolamide 250mg once a day, topical nepafenac 0.1% one drop thrice a day and timolol 0.5% eye drops twice a day. **Discussion:** The main goals of treatment are alleviation of symptoms, including headache, and preservation of vision. Steroids were commonly used for treating IIH in the past, but cause significant long - term side effects, such as weight gain, that are undesirable in IIH patients. Furthermore, withdrawal of steroids can cause rebound intracranial hypertension. Thus, steroids should not be used routinely for IIH treatment. **Results:** By the end of one month, patient was relieved of symptoms, best corrected visual acuity was 6/6 in both eyes with normal IOP, normal optic disc in both eyes. **Conclusion:** Steroids are an effective way of managing idiopathic intracranial hypertension in pediatric patients.*

Keywords: uncontrolled longstanding headache, disc edema, CSF opening pressure, systemic steroids

1. Introduction

Idiopathic intracranial hypertension (IIH, pseudotumor cerebri) is a syndrome of elevated intracranial pressure of unknown cause that occurs predominantly in obese women of childbearing age. It is a diagnosis of exclusion and, therefore, other causes of increased intracranial pressure must be sought with history, imaging, and cerebrospinal fluid examination before the diagnosis can be made. Headache is the most common symptom reported by IIH patients at presentation^{1, 2}.

2. Case Report

A 15 year old girl presented in our OPD at Manjunatha eye hospital, Kundapura, Udupi with headache since 3months, more in the posterior aspect, continuous type with severe intensity, non - radiating. On examination, her best corrected visual acuity in right eye was 6/9 and left eye was 6/6parts. She had normal anterior segment, normal intraocular pressures in both eyes. Fundus examination showed both optic discs edematous, pink in color with blurry disc margins, tortuous disc vessels, edematous peripapillary area. Normal foveolar reflex with normal retinal periphery. (fig 1a, b)

Patient had been evaluated in a tertiary care hospital and her blood reports were normal. Neurological evaluation was also done and lumbar puncture done showed high opening pressure of CSF with normal CSF composition. Hence pseudotumor cerebri was diagnosed. She was using oral acetazolamide 250mg three times a day for a period of one month which showed no improvement.

She was started on oral prednisolone 1mg/kgbw once a day dosage, oral acetazolamide 250mg once a day, topical nepafenac 0.1% one drop thrice a day and timolol 0.5% eye drops twice a day for a period of 2weeks. On follow up, patient was relieved of symptoms and disc edema has also

reduced in the next visit. Later her oral prednisolone was tapered on weekly basis and rest of the medications were continued.

By the end of one month, patient was relieved of symptoms, best corrected visual acuity was 6/6 in both eyes with normal IOP and left optic disc were normal with regular well defined margins and normal vessels. Right optic disc was mildly edematous with ill defined nasal margins and rest of the margins were well defined. Patient was advised to continue oral prednisolone in weekly tapering dose with topical anti - inflammatory and anti - glaucoma agents. By the end of 2months, patient was completely fine with normal vision, normal optic disc with well defined margins. (fig 2a, b) She was followed up for a period of 12months at 2monthly basis and was found to maintain the normal state.

Informed consent has been taken from the patient and patient's mother.

3. Discussion

The main goals of treatment are alleviation of symptoms, including headache, and preservation of vision.³ Steroids were commonly used for treating IIH in the past, but cause significant long - term side effects, such as weight gain, that are undesirable in IIH patients. Furthermore, withdrawal of steroids can cause rebound intracranial hypertension^{4,5}. Thus, steroids should not be used routinely for IIH treatment. High - dose intravenous steroids can, however, be useful for short - term treatment of patients with fulminant disease while a more definitive intervention (e. g., optic nerve sheath fenestration or cerebrospinal fluid shunting) is awaited^{6, 7, 8, 9, 13}. There are other studies supporting the safe use of acetazolamide up to 4 g daily with weight loss for effective treatment of mild vision loss in IIH, with associated improvements in papilledema, increased intracranial pressure, and quality of life^{8, - 15}.

In our study, the patient was already on acetazolamide for a long duration, but did not show any signs of improvement in symptoms or in disc edema.

4. Conclusion

Steroids are an effective way of management of idiopathic intracranial hypertension in pediatric patients not responding to acetazolamide single therapy. This also avoids the risk of surgical intervention in pediatric patients.

References

- [1] Wall M, George D. Idiopathic intracranial hypertension: a prospective study of 50 patients. *Brain*.1991; 114: 155–180.
- [2] Giuseffi V, Wall M, Siegel PZ, Rojas PB. Symptoms and disease associations in idiopathic intracranial hypertension (pseudotumor cerebri): a case - control study. *Neurology*.1991; 41: 239–244.
- [3] Matthew J. Thurtell, Michael Wall. Idiopathic Intracranial Hypertension (Pseudotumor Cerebri): Recognition, Treatment, and Ongoing Management. *Curr Treat Options Neurol*.2013 February; 15 (1): 1–12.
- [4] Liu GT, Kay MD, Bienfang DC, Schatz NJ. Pseudotumor cerebri associated with corticosteroid withdrawal in inflammatory bowel disease. *Am J Ophthalmol*.1994; 117: 352–357.
- [5] Neville BG, Wilson J. Benign intracranial hypertension following corticosteroid withdrawal in childhood. *BMJ*.1970; 3 (5722): 554–556.
- [6] Thambisetty M, Lavin PJ, Newman NJ, Biousse V. Fulminant idiopathic intracranial hypertension. *Neurology*.2007; 68: 229–232.
- [7] Liu GT, Glaser JS, Schatz NJ. High - dose methylprednisolone and acetazolamide for visual loss in pseudotumor cerebri. *Am J Ophthalmol*.1994; 118: 88–96
- [8] Smith SV, Friedman DI. The Idiopathic Intracranial Hypertension Treatment Trial: A Review of the Outcomes. *Headache*.2017 Sep; 57 (8): 1303 - 1310. doi: 10.1111/head.13144. Epub 2017 Jul 30. Erratum in: *Headache*.2018 Nov; 58 (10): 1697. PMID: 28758206.
- [9] Wall M, Johnson CA, Cello KE, et al.; for the NORDIC Idiopathic Intracranial Hypertension Study Group. Visual field outcomes for the Idiopathic Intracranial Hypertension Treatment Trial (IIHTT). *Invest Ophthalmol Vis Sci*.2016; 57: 805–812. DOI: 10.1167/iovs.15 - 18626
- [10] Wall M, Kupersmith MJ, Kiebertz KD, Corbett JJ, Feldon SE, Friedman DI, Katz DM, Keltner JL, Schron EB, McDermott MP; NORDIC Idiopathic Intracranial Hypertension Study Group. The idiopathic intracranial hypertension treatment trial: clinical profile at baseline. *JAMA Neurol*.2014 Jun; 71 (6): 693 - 701. doi: 10.1001/jamaneurol.2014.133. PMID: 24756302; PMCID: PMC4351808.
- [11] Mollan SP, Davies B, Silver NC, et al. *J Neurol Neurosurg Psychiatry* 2018; 89: 1088–1100.
- [12] Markey KA, Mollan SP, Jensen RH, et al. Understanding idiopathic intracranial hypertension: mechanisms, management, and future directions. *Lancet Neurol* 2016; 15: 78–91.
- [13] Spitze A, Malik A, Al - Zubidi N, et al. Optic nerve sheath fenestration vs cerebrospinal diversion procedures: what is the preferred surgical procedure for the treatment of idiopathic intracranial hypertension failing maximum medical therapy? *J Neuroophthalmol* 2013; 33: 183–8.
- [14] Degnan AJ, Levy LM. Pseudotumor cerebri: brief review of clinical syndrome and imaging findings. *AJNR Am J Neuroradiol* 2011; 32: 1986–93
- [15] Yri HM, Rönnbäck C, Wegener M, et al. The course of headache in idiopathic intracranial hypertension: a 12 - month prospective follow - up study. *Eur J Neurol* 2014; 21: 1458–64

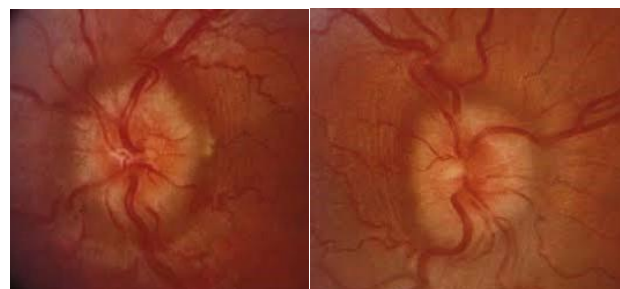


Figure 1 (a)

Figure 1 (b)

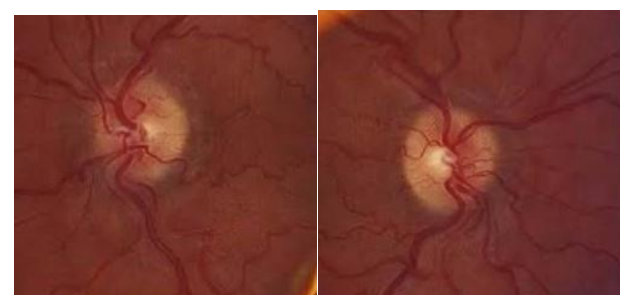


Figure 2 (a)

Figure 2 (b)