

# Recurrent Appendicitis: Clinical Presentation, Diagnostic Challenges, and Surgical Management

Bruostno Douzarros

Instituto Técnico Educacional Souza Marques, Rio de Janeiro, Brazil

**Abstract:** *This article presents a case report of a 23 - year - old male patient with recurrent appendicitis, characterized by repeated episodes of acute abdominal pain in the lower right quadrant. Despite multiple prior diagnoses, the patient's condition was confirmed through a CT scan revealing a thickened retrocecal appendix. Surgical intervention resulted in clinical improvement, highlighting the importance of considering recurrent appendicitis in cases of non - specific abdominal pain to prevent potential complications.*

**Keywords:** Recurrent appendicitis, clinical presentation, diagnostic challenges, surgical management, abdominal pain

## 1. Introduction

Recurrent appendicitis is a pathological condition that differs from acute appendicitis and has an approximate incidence of 10%. It is characterized by recurrent bouts of acute appendicitis. The objective of this work is to report the case of a patient whose clinical presentation was made with recurrent appendicitis.

## 2. Case Report

Male, 23 - year - old patient with a 3 - year history of 5 episodes of severe and diffuse abdominal pain that radiated to the right side of the abdomen with no specific location, reporting constipation and nausea. Denies fever or vomiting.

The patient sought an outpatient clinic where he was diagnosed with gastroenteritis, with blood count and ultrasound showing no alterations. In 2021 he also performed colonoscopy in which he was normal. In the last crisis, in May 2022, the patient sought the emergency room, where he underwent a CT scan of the abdomen for the first time (Image 1), in which a thickened retrocecal appendix measuring 13.4 mm in the longest axis, pericecal and periappendiceal blurring, could be observed. On the same day he performed videolaparoscopic appendectomy.

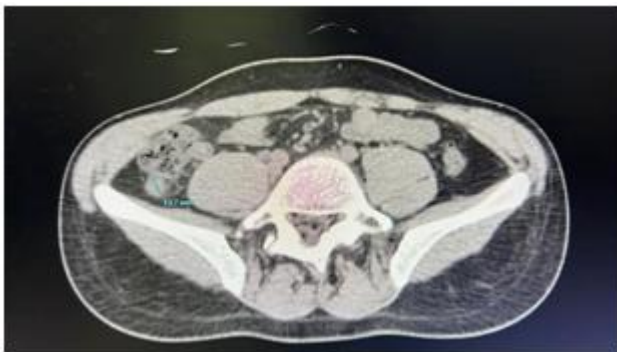


Image 1

## 3. Conclusion

Recurrent appendicitis, although less common than acute appendicitis, presents a distinct clinical profile of repeated lower right quadrant abdominal pain. This case report aligns with existing literature, emphasizing the need for early consideration and accurate diagnosis to avoid complications like perforation. While the pathophysiology remains uncertain, probable causes include partial or transient obstruction due to anatomical variations. The limited sensitivity of ultrasonography underscores the value of computed tomography scans for better visualization.

Recognizing the potential for serious outcomes, recurrent appendicitis should be part of the differential diagnosis for non - specific abdominal pain, encouraging timely intervention and improved patient outcomes.

## References

- [1] SAAD, Melissa Kyriakos; AOUN, Rami; GHANDOUR, Fatme; SAIKALY, Elias. \_Recurrent Appendicitis: Torsion Detorsion of the Appendix. \_ Dubai Medical Journal, 2022. Available at: <<https://www.karger.com/Article/Pdf/523722>>. Accessed on: May 16, 2022.
- [2] MENGESHA, MD; TEKLU, GG. A case report on recurrent appendicitis: An often forgotten and atypical cause of recurrent abdominal pain. Elsevier Ltd, 2018. Available at: <https://www.ncbi.nlm.nih.gov/pmc/articles/PMC5938417/#!po=74.0000>. Accessed on: May 22, 2022.
- [3] ROCHA, JR; APRILLI, F; FÉRES, O. Chronic appendicitis and recurrent appendicitis. Review article and casuistic presentation. *Medicine*, Ribeirão Preto, 34, 292 - 296, Jul. /Dec.2001. Available at: <https://www.revistas.usp.br/rmrp/article/view/4403/5749>. Accessed on: May 22, 2022.
- [4] Hawes AS, Whalen GF. Recurrent and chronic appendicitis: the other inflammatory conditions of the appendix. *Am Surg*.1994 Mar; 60 (3): 217 - 9. PMID: 8116986. Available at: <<https://pubmed.ncbi.nlm.nih.gov/8116986/>>. Accessed on: May 23, 2022.